Brazilian
JOURNAL OF HEALTH AROMATHERAPY AND ESSENTIAL OIL

Case Report

Aromatherapy for Unifocal Alopecia Areata and Dermatitis: A Case Report

Elisama Ribeiro dos Santos [1,*]

[1] Instituto Aromas da Terra Pesquisa e Educação, Fortaleza, Ceara, Brazil.
[2] Centro Universitário de Tecnologia de Curitiba – UNIFATEC, Curitiba, Paraná, Brazil.

* Correspondence: elisama-m12@hotmail.com.

Abstract: The present narrative review focuses on exploring the role of essential oils as a significant intervention in stress management. Stress, defined as an adaptive response to challenging stimuli, manifests in various spheres, with its approach being essential for the preservation of physical and emotional well-being. Essential oils present themselves as bioactive agents whose impact occurs on the nervous system through olfactory and cutaneous pathways, directly influencing emotional processes, memories, mood, and behavior. Notable among these essential oils are lavender, chamomile, and bergamot, recognized for their anti-stress properties. The application of these essential oils, whether through inhalation or cutaneous administration, demonstrates efficacy in promoting beneficial physiological and psychological effects. Individualization of treatment is emphasized, considering synergies, affinities, and personal preferences. The diversity of products, including diffusers and creams, amplifies application options, offering a flexible and personalized approach. In the clinical realm, the inclusion of essential oils in the stress management protocol is supported by their ability to modulate emotional responses and promote states of relaxation. In summary, essential oils emerge as a prominent and customizable strategy in stress treatment, contributing significantly to the promotion of physical and emotional balance in individuals.

Keywords: Essential Oils; Alopecia Areata; Dermatitis; Individualized Treatment.

Citation: Santos RE. Evaluation of the effects of essential oils on the reduction of stress: a rapid narrative review. Brazilian Journal of Aromatherapy and Essential Oil. 2024;1: bjhae5.

doi: https://doi.org/10.62435/2965-7253.bjhae.2024.bjhae5

Received: 18 January 2024
Accepted: 19 February 2024
Published: 23 March 2024

Copyright: This work is licensed under a Creative Commons Attribution 4.0 International License (CC BY 4.0).

1. Introduction

Alopecia areata (AA) is a chronic autoimmune disorder that causes hair loss in patches [1, 2]. Dermatitis is a general term for inflammation of the skin, which can have various causes and symptoms [3]. Both conditions can affect the quality of life and psychological well-being of the patients. There is no definitive cure for AA or dermatitis, and the treatments available are often associated with side effects, low efficacy, or high cost. Therefore, some patients may seek alternative or complementary therapies, such as aromatherapy, to manage their symptoms and improve their emotional state [1-3].

Aromatherapy is the use of essential oils extracted from plants for therapeutic purposes. Essential oils can be applied topically, inhaled, or diffused in the environment. Some of the benefits of aromatherapy include anti-inflammatory, antimicrobial, antioxidant, analgesic, and mood-enhancing effects. In this case report, we present the successful use of aromatherapy for a female patient with unifocal AA and dermatitis, who experienced significant improvement in her hair growth, skin condition, and psychological state after six weeks of treatment [5].

2. Case Report

The patient, a 42-year-old female, presented with severe hair loss and dermatitis. She had been diagnosed with unifocal alopecia areata (AA) (Figure 1) and dermatitis (Figure

2) by a dermatologist. The conditions escalated from unifocal to multifocal alopecia areata and worsened dermatitis over time. The dermatologist prescribed topical corticosteroids and oral antihistamines as conventional treatments. However, despite the medical recommendations, the patient, driven by a high level of emotional and physical pain, expressed a fear of becoming bald and an increasing concern about the exacerbation of her dermatitis, impacting her appearance and overall aesthetic.



Figura 1: Patient diagnosed with Aleopecia Aerata.

In her quest for alternatives, the patient decided against using medications. Instead, she chose to explore natural resources and solutions, turning to the expertise of an aromatherapist for assistance. This decision stemmed from her reluctance to undergo conventional medical treatments and a preference for holistic approaches. Notably, the patient reported that there were no similar cases of alopecia areata or dermatitis within her family history. This unique aspect added complexity to her condition, making her case distinct from familial patterns typically associated with these conditions. Despite the challenges, the patient remained committed to exploring holistic avenues, highlighting the significance of individualized approaches in addressing both physical and emotional aspects of her health.



Figura 2: Patient diagnosed with Demartitis.

2.1 Treatment

The aromatherapist performed a detailed assessment of the patient's medical history, lifestyle, and preferences. Based on the patient's condition and needs, the aromatherapist

designed a personalized treatment plan. Weekly therapy sessions at the aromatherapist's office, which included:

1. Cleansing the scalp and hair with the most natural cosmetic kit possible, containing shampoo, conditioner, and mask with plant extracts and essential oils.
2. Electrotherapy session, using 10 minutes of high frequency and 5 minutes of vacuum therapy, to stimulate blood circulation and oxygenation of the scalp and hair follicles.
3. Microneedling session, using a dermaroller with 0.5mm or 0.25mm needles, to create micro-injuries on the scalp and enhance the absorption of the essential oils.
4. Application of a blend of essential oils on the scalp and hair, after microneedling, and massage for 10 minutes.

Home care, which included:

1. Application of the same blend of essential oils on the scalp and hair, at the hair loss area, three times a week, always at bedtime, preferably without washing the hair.
2. Inhalation of the essential oils, using a diffuser or a cotton pad, whenever the patient felt stressed, anxious, or depressed.



Figura 3: Result of treatment with essential oils in a patient diagnosed with Aleopecia Aerata and Dermatitis.

The blend of essential oils (10mL) was composed of:

1. 15 drops of lavender oil (*Lavandula angustifolia*), which has anti-inflammatory, antiseptic, soothing, and relaxing properties.
2. 15 drops of rosemary oil (*Rosmarinus officinalis*), which has anti-inflammatory, antimicrobial, antioxidant, and hair growth-promoting properties.
3. 10 drops of peppermint oil (*Menta peperita*), which has anti-inflammatory, analgesic, cooling, and stimulating properties.
4. 15 drops of cedar oil (*Juniperus virginiana*), which has anti-inflammatory, antifungal, astringent, and hair growth-promoting properties.

The blend of essential oils was diluted in a carrier oil, such as jojoba oil or coconut oil, at a concentration of 10% for the office sessions and 25% for the home care. The patient followed the treatment plan for six consecutive weeks, with a total of six office sessions and 18 home applications. The patient did not use any other medication or therapy during the treatment period.

The patient opted for a medication-free approach and exclusively relied on the application of essential oils, both topically and aromatically, as part of rituals such as relaxing massages and hair therapy. This holistic regimen was complemented by weekly therapeutic sessions, featuring a meticulous cleansing routine using the most natural cosmetic kit available. During these sessions, the patient underwent a comprehensive treatment plan, which included eletrotherapy, micro-needling, and a specialized blend of essential oils. The combination of these therapeutic modalities aimed to address the patient's specific concerns, offering a holistic and natural alternative to conventional medical interventions.

2.2 Clinical follow-up

Figure 1 illustrates the follow-up of a challenging case of Alopecia Areata, where the patient's progress over the course of a year was both remarkable and enlightening. Initially diagnosed with unifocal Alopecia Areata on November 19, 2021, the patient's condition quickly escalated to multifocal Alopecia Areata by November 23, 2021. This rapid progression underscored the urgency and complexity of the case.

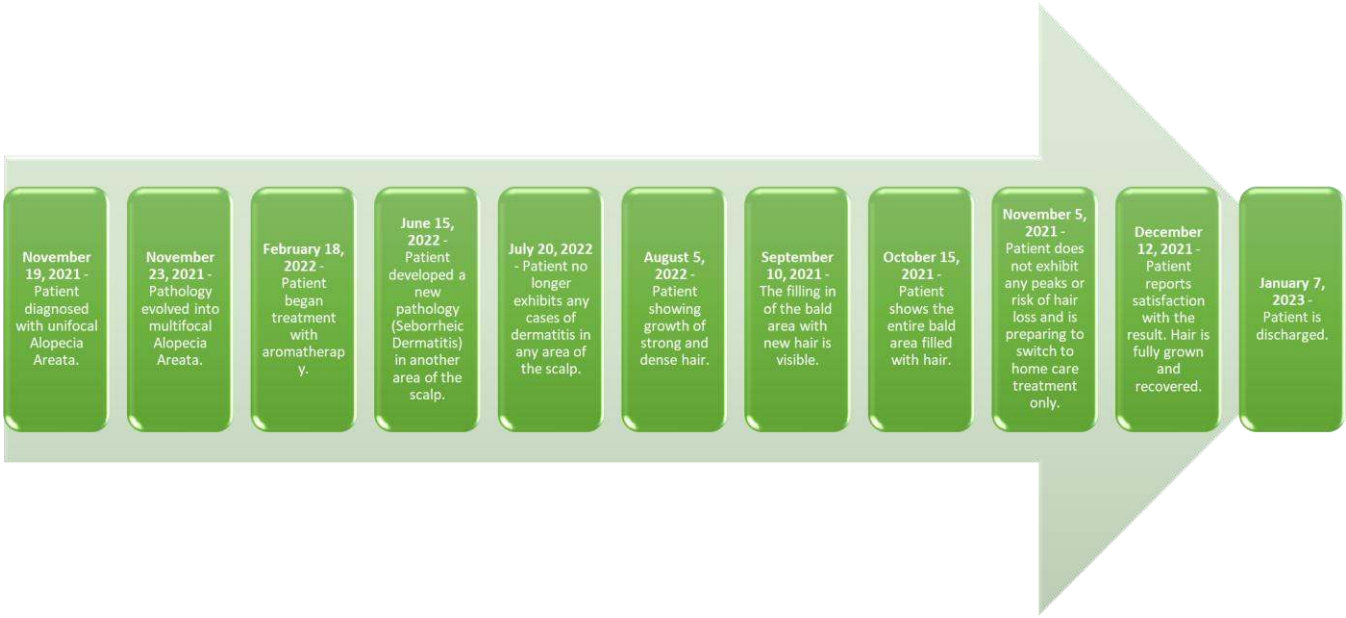

Figure 4: Aromatherapy Treatment for a Patient Diagnosed with Alopecia Areata.

In response to these developments, the patient embarked on an aromatherapy treatment regimen on February 18, 2022. Utilizing a carefully crafted blend of essential oils, this approach was tailored to address the underlying causes of hair loss. The essential oils, known for their various therapeutic properties, were applied topically, and used for inhalation to create a holistic healing environment. As the treatment progressed, an unexpected challenge emerged. On June 15, 2022, the patient developed Seborrheic Dermatitis in a different region of the scalp. This development required a slight adjustment in the treatment protocol, emphasizing the adaptability and resilience of both the patient and the therapeutic approach.

Encouragingly, by July 20, 2022, there were no longer any signs of dermatitis. This marked a significant milestone in the patient's recovery journey. Following this, on August 5, 2022, there was noticeable regrowth of strong and dense hair, indicating a positive response to the treatment. By September 1, 2022, the hair continued to grow without any complications, and by September 10, 2022, the previously bald areas began showing significant coverage with new hair growth. This progress was further consolidated on October 15, 2021, when the bald areas were filled with new hair.

As the patient approached the end of the treatment cycle, by November 5, 2021, there were no signs of hair loss relapse. The patient was preparing to transition to a home care-only regimen. By December 12, 2021, the patient expressed satisfaction with the outcome, showcasing a full recovery of hair growth. Finally, on January 7, 2023, the patient was officially discharged, marking the end of a successful therapeutic journey. This case not only highlighted the effectiveness of aromatherapy in treating complex hair loss conditions but also demonstrated the importance of a patient-centered and adaptable approach in medical treatments.

3. Discussion and conclusion

This case report demonstrates the potential benefits of aromatherapy for a patient with unifocal AA and dermatitis, who achieved significant improvement in her hair growth, skin condition, and psychological state after six weeks of treatment. The patient reported a reduction in hair loss, itching, and inflammation, as well as an increase in hair density, volume, and shine. She also reported a decrease in stress, anxiety, and depression, and an increase in self-esteem, confidence, and well-being. These results are consistent with previous studies that have shown the positive effects of aromatherapy on hair and skin disorders, as well as on mood and quality of life [5, 6].

The mechanism of action of aromatherapy for alopecia areata (AA) and dermatitis is not fully understood, but it may involve several factors. These include the anti-inflammatory, antimicrobial, antioxidant, and analgesic properties of essential oils. These properties may modulate the immune system, reduce oxidative stress, and relieve pain and discomfort. Additionally, aromatherapy may stimulate blood circulation and oxygenation of the scalp and hair follicles, enhancing the delivery of nutrients and the removal of toxins, ultimately promoting hair growth [7, 8]. Another aspect is the activation of the olfactory system and limbic system, which may regulate the hypothalamic-pituitary-adrenal (HPA) axis, the autonomic nervous system, and the endocrine system. This regulation can influence the production and release of hormones, neurotransmitters, and neuropeptides, such as cortisol, serotonin, and endorphins. These biochemical changes may affect the hair cycle, the skin barrier, and the emotional state [9].

The strengths of this case report include the personalized and holistic approach of the aromatherapy treatment, which was tailored to the patient’s condition and needs, and the use of objective and subjective measures to evaluate the outcomes, such as photographic assessment, trichoscopy, dermatoscopy, and self-reported questionnaires. The limitations of this case report include the small sample size, the lack of a control group, and the short follow-up period, which limit the generalizability and the validity of the results. Therefore, further studies with larger samples, randomized controlled trials, and

longer follow-up periods are needed to confirm the efficacy and safety of aromatherapy for AA and dermatitis, and to elucidate the underlying mechanisms of action. Moreover, future research should also explore the optimal dosage, frequency, duration, and combination of essential oils for different types of AA and dermatitis, and the possible interactions and adverse effects of aromatherapy with other medications or therapies.

4. Conclusion

In conclusion, this case report suggests that aromatherapy may be a safe and effective alternative or complementary therapy for patients with unifocal AA and dermatitis, who may benefit from the physical, emotional, and cosmetic effects of the essential oils. Aromatherapy may also improve the patient's adherence and satisfaction with the treatment, and reduce the need for conventional medications, which may have undesirable side effects or high costs. However, more evidence-based research is required to support the clinical use of aromatherapy for AA and dermatitis, and to provide guidelines and recommendations for practitioners and patients.

Funding: None.

Research Ethics Committee Approval: The study, conducted in accordance with the Declaration of Helsinki, followed ethical guidelines, ensuring adherence to principles and obtaining the patient's informed consent.

Acknowledgments: None.

Conflicts of Interest: None.

Supplementary Materials: None.

References

1. Ho CY, Wu CY, Chen JY, Wu CY. Clinical and Genetic Aspects of Alopecia Areata: A Cutting Edge Review. Genes (Basel). 2023 Jun 28;14(7):1362. doi: 10.3390/genes14071362. PMID: 37510267; PMCID: PMC10379312.
2. Dahabreh D, Jung S, Renert-Yuval Y, Bar J, Del Duca E, Guttman-Yassky E. Alopecia Areata: Current Treatments and New Directions. Am J Clin Dermatol. 2023 Nov;24(6):895-912. doi: 10.1007/s40257-023-00808-1. Epub 2023 Aug 22. PMID: 37606849.
3. Maibach HI, Fowler JF, Zirwas MJ, editors. Fisher's Contact Dermatitis. 7th ed. Raleigh (NC): PMPH USA; 2018. 800 p. ISBN-13: 9781607951896. Review by: [No author listed]. British Journal of Dermatology. 2019 Aug;181(2):425-426.
4. Schaller M, Korting HC. Allergie airborne contact dermatitis from essential oils used in aromatherapy. Clin Exp Dermatol. 1995 Mar;20(2):143-145. doi: 10.1111/j.1365-2230.1995.tb02719.x.
5. Hay IC, Jamieson M, Ormerod AD. Randomized trial of aromatherapy. Successful treatment for alopecia areata. Arch Dermatol. 1998 Nov;134(11):1349-52. doi: 10.1001/archderm.134.11.1349. PMID: 9828867.
6. Hwang A, Brady K, Liu R, Lio P. Complementary and Alternative Therapies for Alopecia Areata. J Integr Dermatol. 2022 Nov 25.
7. Abelan US, de Oliveira AC, Cacoci ÉSP, Martins TEA, Giacon VM, Velasco MVR, Lima CRRC. Potential use of essential oils in cosmetic and dermatological hair products: A review. J Cosmet Dermatol. 2022 Apr;21(4):1407-1418. doi: 10.1111/jocd.14286. Epub 2021 Jun 23. PMID: 34129742.
8. Peterle L, Sanfilippo S, Borgia F, Cicero N, Gangemi S. Alopecia Areata: A Review of the Role of Oxidative Stress, Possible Biomarkers, and Potential Novel Therapeutic Approaches. Antioxidants (Basel). 2023 Jan 6;12(1):135. doi: 10.3390/antiox12010135. PMID: 36670997; PMCID: PMC9854963.
9. Zhang X, Yu M, Yu W, Weinberg J, Shapiro J, McElwee KJ. Development of alopecia areata is associated with higher central and peripheral hypothalamic-pituitary-adrenal tone in the skin graft induced C3H/HeJ mouse model. J Invest Dermatol. 2009 Jun;129(6):1527-38. doi: 10.1038/jid.2008.371. Epub 2008 Nov 20. PMID: 19020552; PMCID: PMC4853312.