*Original Article*

# EVALUATION OF THE EFFECTIVENESS OF INTRAOPERATIVE ULTRASONOGRAPHY IN THE IDENTIFICATION OF INTRA-ARTICULAR SCREWS AND LONG SCREWS

**Manuel Agnelo dos Santos Junior**[1, *]

[1] Filiação: Getúlio Vargas Hospital, Recife, Pernambuco, Brazil.
* Correspondence: agnelojr@outlook.com

**Abstract:** Surgery with plates and screws is commonly indicated for unstable distal radius fractures, and accurate assessment of screw length and positioning is essential. Conventional intraoperative fluoroscopy and radiography may fail to identify excessively long or intra-articular screws. This study evaluated the effectiveness of intraoperative ultrasonography in detecting screw positioning abnormalities during distal radius fixation. A prospective clinical study included 12 patients with distal radius fractures or malunions who underwent osteosynthesis or corrective osteotomy with plates and screws at a Brazilian hand surgery referral center. After fixation, multiple fluoroscopic views were obtained, followed by intraoperative ultrasonography. Screws were replaced when necessary. Postoperative radiography and computed tomography were subsequently performed, and the findings were statistically analyzed. Participants had a mean age of 50.03 ± 17.6 years (range: 23–76 years), and all injuries were trauma-related. The interval between trauma and surgery ranged from 14 to 23 days. A strong correlation between ultrasonography and fluoroscopic findings was observed in 86% of the evaluated cases (r = 0.854). Postoperative radiography and computed tomography showed no need for additional screw replacement. One patient (8.33%) required surgical revision because of inadequate fracture reduction. Intraoperative ultrasonography proved to be a reliable, accessible, noninvasive, and radiation-free method for evaluating screw length and positioning during distal radius fixation. However, further studies with larger samples and more rigorous methodological designs are required to confirm these findings.

**Keywords:** Ultrasonography; Image intensifier; volar plate; Fracture; Distal radio.

**Citation:** Junior MAS, Evaluation of the Effectiveness of Intraoperative ultrasonography in the Identification of intra-articular screws and Long Screws. Brazilian Journal of Aromatherapy and Essential Oil. 2024.

**doi:** https://doi.org/10.62435/2965-7253.bjhae.2024.

Received: 15 January 2024

Accepted: 18 March 2024

Published: 18 April 2024

**Copyright:** This work is licensed under a Creative Commons Attribution 4.0 International License (CC BY 4.0).

## 1. Introduction

Distal radius fractures are among the most frequently reported injuries in emergency departments worldwide, accounting for 10% to 12% of all fractures in the human body, particularly among older adults. More than 100,000 cases are reported annually in the United Kingdom, while over 600,000 new cases are recorded each year in the United States (1,2). For several decades, these fractures have been a major focus of research and concern among specialists because of their high incidence, variability, and complexity. Brazilian studies report rates ranging from 1% to 31%. Among the mechanisms of injury, road traffic accidents and falls onto an outstretched hand are the most commonly reported (1-3).

Currently, volar plates are the most widely used method for the surgical treatment of distal radius fractures (23). However, extensor tendon irritation caused by excessively long screws and arthropathy resulting from intra-articular screw penetration remain common complications of this technique. Conventional radiographs and fluoroscopic images have proven insufficient for the intraoperative assessment of juxta-articular screw placement (7-10). Even with additional radiographic views, including oblique and so-called skyline views, accurate assessment remains notably difficult (11-15). Other imaging modalities, such as computed tomography (CT) and magnetic resonance imaging (MRI),

provide more reliable findings; however, they cannot be routinely used during surgery and are costly. Ultrasonography (US) is an inexpensive, noninvasive, readily performed imaging method that does not involve ionizing radiation (19). With its increasing use in peripheral nerve blocks, intraoperative ultrasonography is becoming readily available for use during the surgical treatment of distal radius fractures (19).

The aim of this study was to evaluate the effectiveness of ultrasonography in detecting intra-articular and excessively long screws compared with conventional imaging methods.

## 2. Materials and Methods

This prospective clinical study was conducted at a referral center for hand surgery in a major metropolitan area in northeastern Brazil between March 2018 and July 2019. Twelve patients were included, accounting for 13 distal radius fractures, as one patient underwent bilateral surgery. All patients were diagnosed with a distal radius fracture requiring surgical treatment according to instability criteria described in the literature (18,19). Fractures were categorized using the Müller and Gustilo AO classification system. The study was conducted in accordance with the Declaration of Helsinki following approval by the Research Ethics Committee. The inclusion criteria were patients of either sex diagnosed with a distal radius fracture requiring surgical treatment who signed the informed consent form. The exclusion criteria were associated deformities, failure to provide signed informed consent, and the need for additional bone grafting procedures. After fracture classification, all patients underwent surgery performed by the same hand surgery team at the referral hospital.

### Surgical Procedure

All patients were placed in the supine position, with the affected upper limb supported on a hand table. In all cases, anesthesia consisted of an ultrasound-guided brachial plexus block and sedation. The same ultrasound system was used in every procedure (SonoSite L38 NanoMax; 10–5 MHz). The limb was exsanguinated, and a pneumatic tourniquet was applied at the upper-arm level. A modified Henry approach was used in all cases, followed by volar plate and screw fixation. Plate and screw positioning was assessed intraoperatively using fluoroscopy and ultrasonography. The same ultrasound system used by the anesthesiologist was employed in musculoskeletal imaging mode.



**Figure 1 – Patient positioning: supine position with the upper limb supported on a side table. Ultrasound system used for anesthesia and surgery. Pneumatic tourniquet in place.**

**Imaging Assessment**

Intraoperatively, after completion of osteosynthesis, multiple fluoroscopic views were obtained using an image intensifier: skyline, anteroposterior (AP), posteroanterior (PA), pronated oblique, supinated oblique, and lateral views with 20° caudocranial angulation. Intraoperative ultrasonography was then performed. Screws were replaced whenever necessary. After surgery, conventional radiographs and computed tomography scans were obtained.

For ultrasonographic examination, the transducer was placed inside a sterile glove containing conductive gel, and its cable was covered with a sterile plastic sheath. Conventional ultrasonography was then performed to evaluate all extensor fibro-osseous compartments, as well as the radiocarpal and distal radioulnar joints. Because ultrasound waves cannot penetrate the bony cortex, and screws should ideally remain entirely within the distal radial epiphysis without breaching any cortex, the screws were not expected to be visualized. Whenever a screw was visible, its placement was considered inadequate.



**Figure 2 – Intraoperative ultrasonography used to assess the adequacy of screw placement. The upper ultrasound image shows no screws protruding beyond the cortex. The lower image shows the characteristic hyperechoic appearance of a protruding screw that required replacement. The ultrasound system used for all patients is shown on the right.**



**Figure 3 – Transducer and conductive gel enclosed in a sterile glove, with the cable covered by a sterile plastic sheath.**



**Figure 4 – Postoperative radiographs (oblique and PA views) showing uncertainty regarding screw penetration into the radiocarpal joint. Postoperative CT images in the coronal and axial planes confirmed that no penetration had occurred. Intraoperative ultrasonography was essential for assessing screw placement.**

### 3. Statistical Analysis

The normality of the collected data was initially assessed using the Kolmogorov–Smirnov test. Descriptive data were expressed as percentages and means, whereas parametric data were reported as means and standard deviations. Statistical analyses were performed using SPSS software. Spearman's correlation coefficients were calculated to assess associations between the imaging findings. Differences between imaging methods were evaluated using Student's t-test. Statistical significance was set at $p < 0.05$.

### 3. Results

### Sample Characteristics

The study included 12 patients, most of whom were male (male, n = 7; female, n = 5), corresponding to 58.3% men and 41.6% women. The mean age of the participants was 50.03 ± 17.60 years (range, 23–76 years). The left side was affected in 53.8% (n = 6) of the cases. The mechanism of injury was a motorcycle accident (collision and/or pedestrian–motorcycle accident) in six cases (50%), followed by falls from a height (stairs, scaffolding, or buildings) in two cases (16.6%), ground-level falls in three cases (25.0%), and a work-related crushing injury in one case (8%). Fractures were classified according to the AO classification criteria (Figure 10). The interval between injury and definitive osteosynthesis ranged from 4 to 34 days (Figure 11).

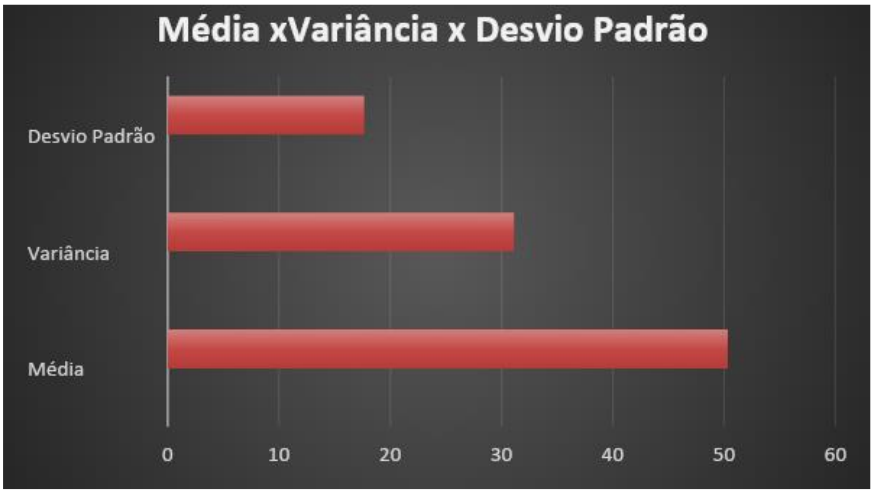


**Figure 5 – Mean, variance, and standard deviation of the patients' ages in the study sample.**

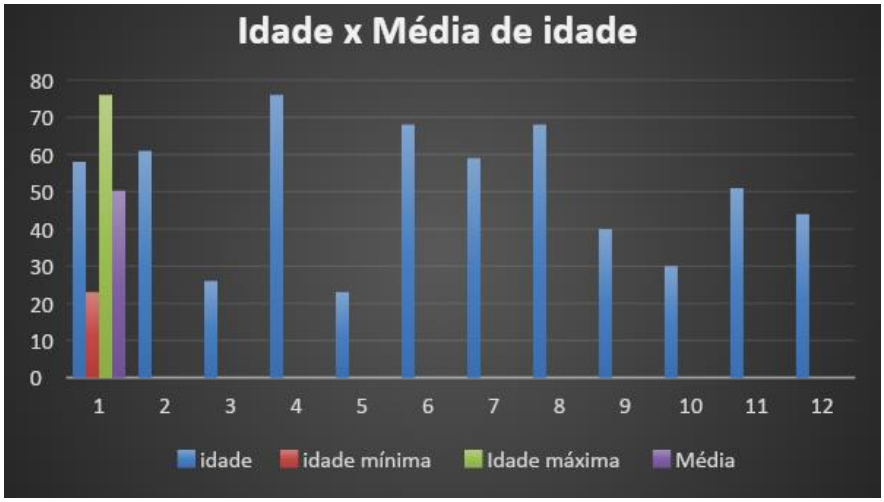


**Figure 6 – Minimum and maximum ages and mean age of the study sample.**

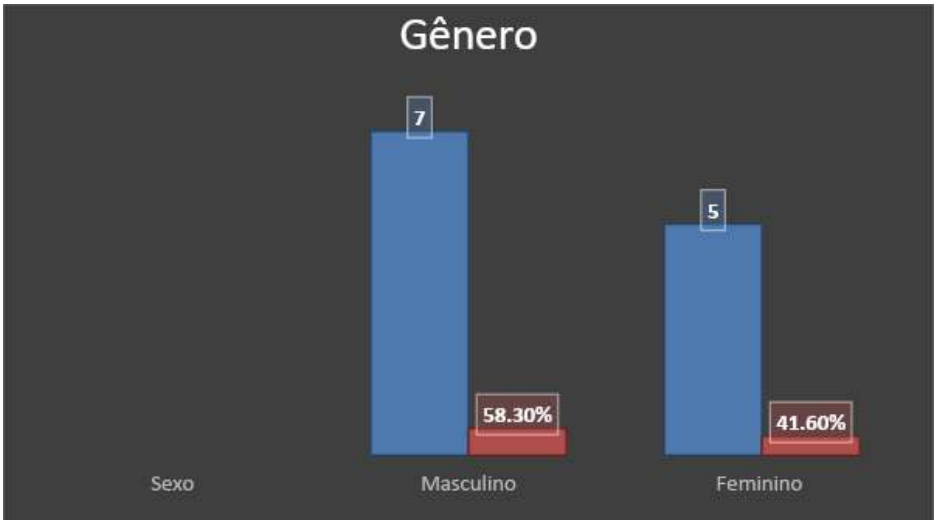

**Figure 7 – Percentage distribution of male and female participants.**

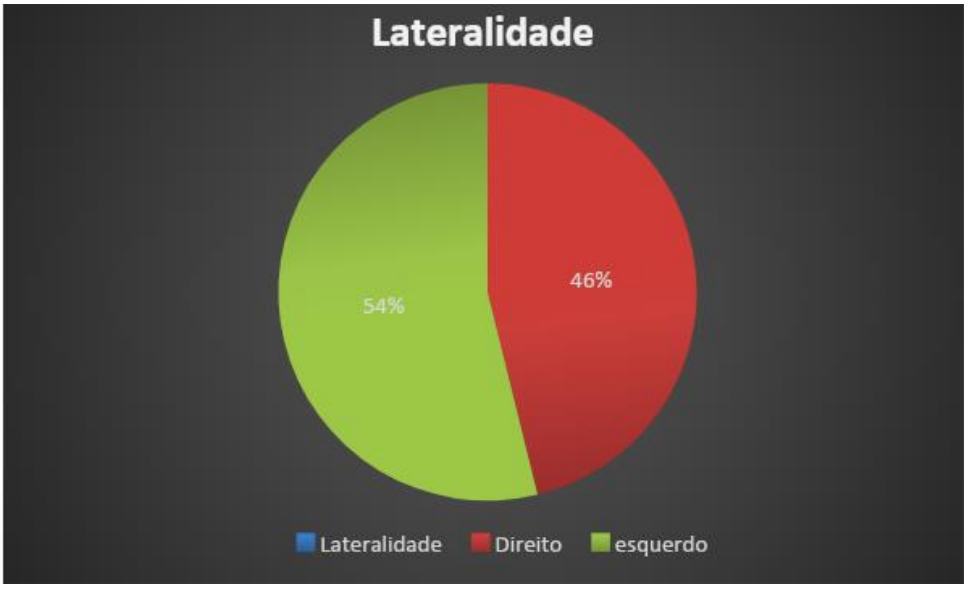


**Figure 8 – Laterality of the fracture, with the left side being more frequently affected.**

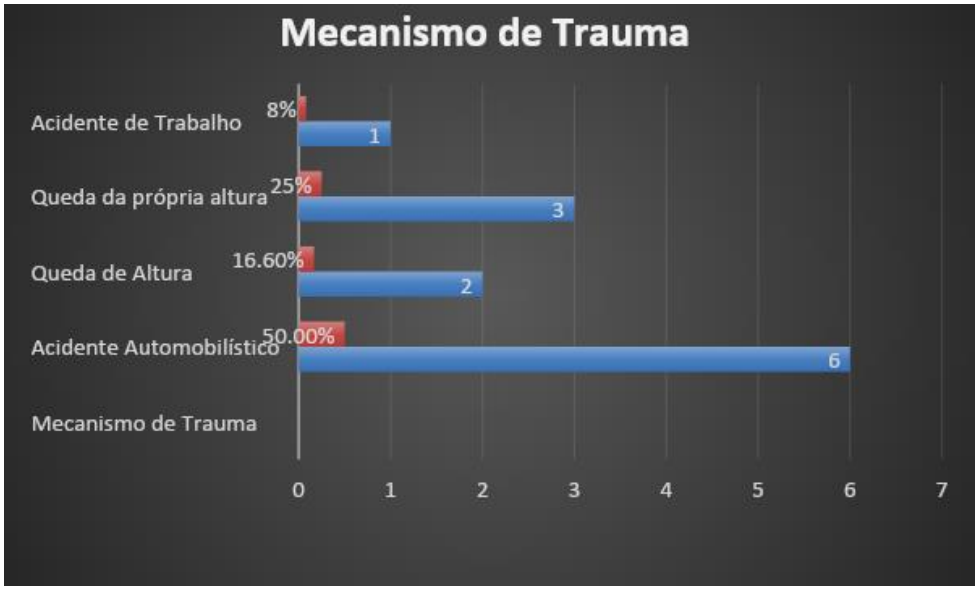

**Figure 9 – Mechanism of injury.**

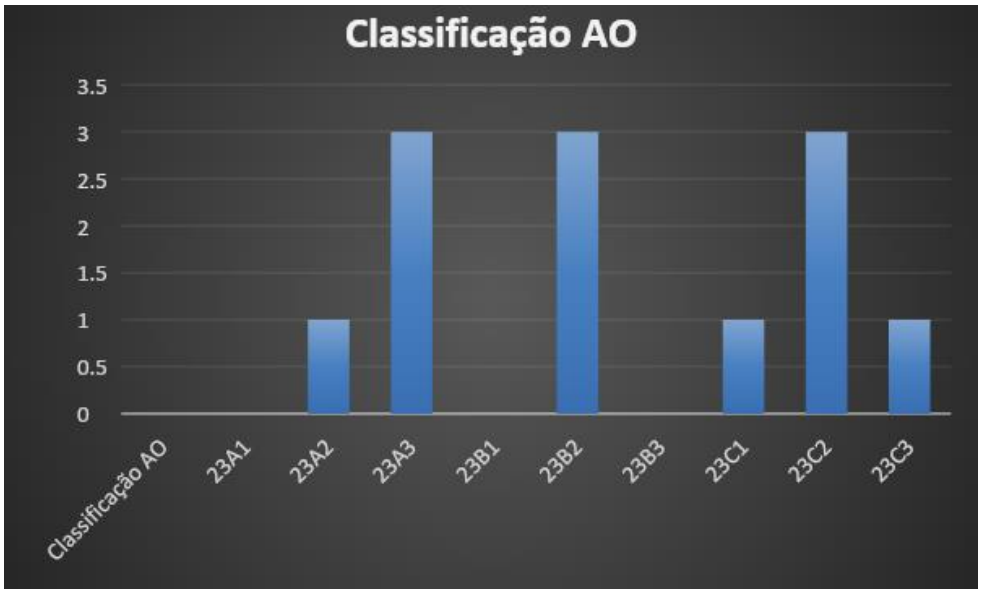


**Figure 10 – AO fracture classification.**

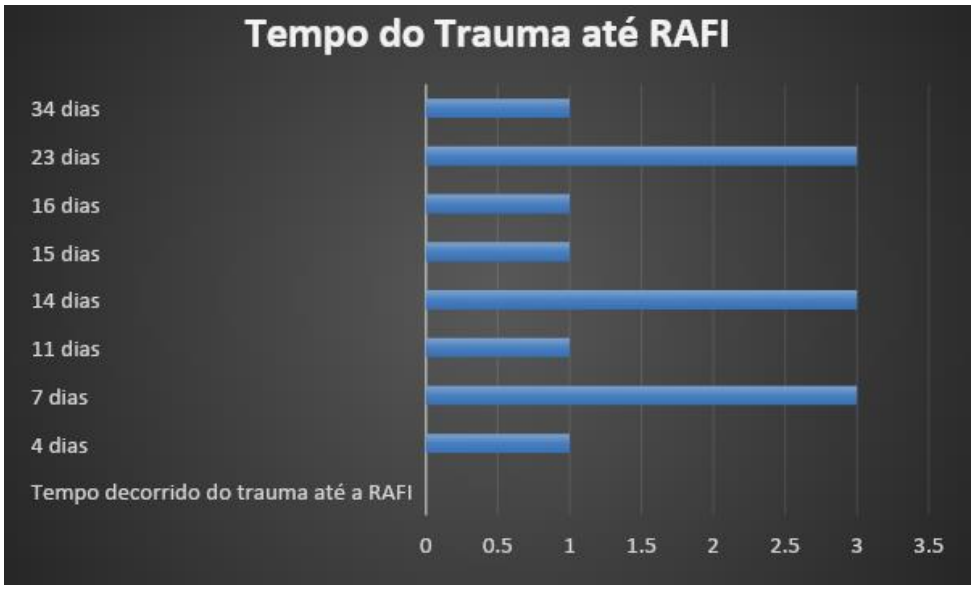


**Figure 11 – Time elapsed from injury to definitive osteosynthesis.**

**Clinical Evaluation**

During surgery, screw replacement was required in nine patients, despite fluoroscopy showing no indication for replacement. In four patients, only one screw required replacement because it protruded beyond the dorsal cortex. In three patients, two screws required replacement because they protruded more than 1 mm beyond the dorsal cortex. One patient required replacement of three screws, while another had four screws considered inadequately positioned

and subsequently replaced. Postoperative radiographs and CT scans showed no indication for further screw replacement. In one case (8.33%), surgical revision was required because of inadequate fracture reduction.

A strong positive correlation was observed between ultrasonography and image intensifier findings in 86% (n = 10) of the evaluated cases (r = 0.958) (Table 1; Figure 12).

In all cases, ultrasonographic assessment was essential, as it reduced the risk of complications and minimized radiation exposure for both the surgical team and the patients.

**Table 1 – Variables collected from intraoperative ultrasonography and fluoroscopy findings.**

| | Ultrassom | Intensificador de Imagens |
|---|---|---|
| Mínimo | 0,0 | 0,0 |
| Máximo | 5,000 | 4,000 |
| | | |
| Média | 1,583 | 1,417 |
| Desvio padrão | 1,443 | 1,240 |
| Desvio do Erro padrão | 0,4167 | 0,3580 |
| | | |
| Lower 95% CI of mean | 0,6683 | 0,6287 |
| Upper 95% CI of mean | 2,500 | 2,205 |
| Wilcoxon (p valor) | 0,167 | |
| Spearman | 0,958 | |

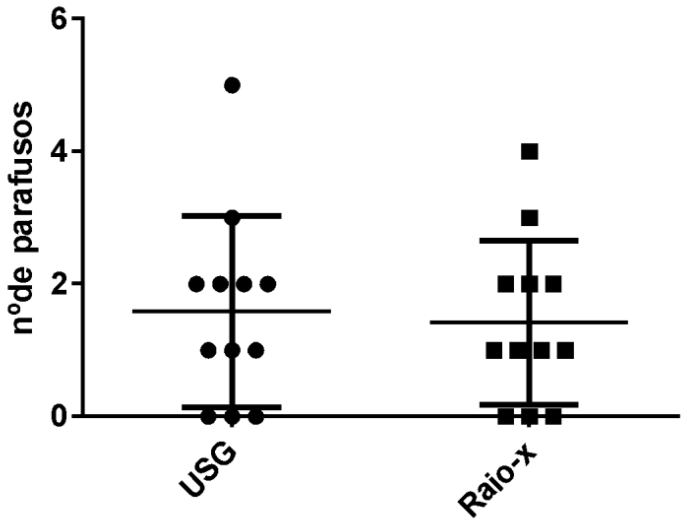


**Figure 12 – Graphical representation of the strong positive correlation between intraoperative ultrasonography and fluoroscopy.**

**Postoperative Imaging Assessment**

Postoperatively, the three imaging modalities were compared using ANOVA to determine whether surgical revision was required because of failure to detect screws protruding beyond the dorsal cortex or penetrating the joint. It was assumed that if postoperative CT identified a screw protruding beyond the dorsal cortex or extending intra-articularly, intraoperative ultrasonography had failed to detect it during surgery. Among the 12 cases evaluated, postoperative CT identified no inadequately positioned screws. Inadequate fracture reduction was identified in only one case.

No statistically significant difference was found among the imaging modalities, and a strong positive correlation was observed among them (p = 0.338; r = 0.869) (Table 2; Figure 13).

**Table 2 – Data obtained from postoperative imaging studies performed to determine the need for surgical revision.**

| | | |
|---|---|---|
| ANOVA | | |
| Assumir esfericidade? | | Não |
| F | | 1,000 |
| Valor p | | 0,3388 |
| Estatisticamente significante (P < 0.05)? | | Não |
| Geisser-Greenhouse's épsilon | | 0,5000 |
| Risco | | 0,08333 |
| | Spearman | |
| | 0,869 | |

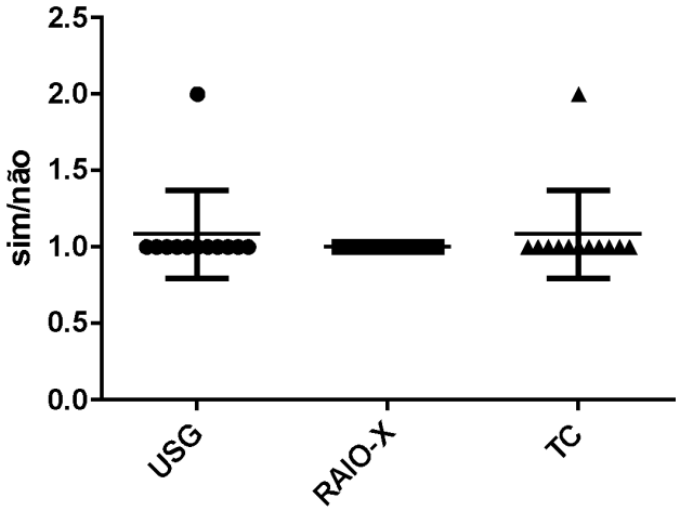

**Figure 13 – Graphical representation of postoperative imaging findings indicating the need for surgical revision, coded as yes = 2 and no = 1.**

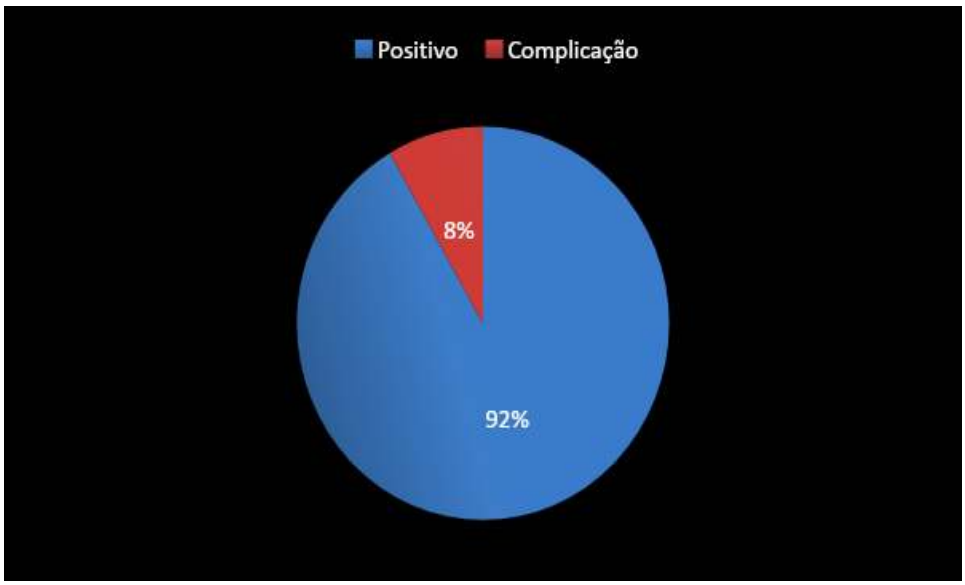


**Figure 14 – Graphical representation of the percentages of positive outcomes and postoperative complications.**

**Discussion**

Volar locking plates have rapidly become the standard method for distal radius fracture fixation (8-13), not only because they reduce the risk of secondary displacement (16), but also because they allow early mobilization and faster clinical recovery. However, several complications have been reported, including extensor tenosynovitis caused by epiphyseal screws protruding beyond the dorsal cortex of the radius and arthropathy secondary to intra-articular screw penetration (7-9).

Several authors have demonstrated the benefits of fluoroscopy for the intraoperative assessment of epiphyseal screw placement (11-13). However, the use of ionizing radiation appears to limit its widespread recommendation, although some studies have shown that radiation exposure to the surgical team is minimal (9).

It is widely recognized that radiographic imaging alone is insufficient to detect screw penetration into the second and fourth extensor compartments. Several authors have compared radiography with other imaging modalities and demonstrated differences in detection accuracy (12-23). Gurbuz et al. (15) evaluated ten cadaveric forearms that underwent surgery followed by ultrasonographic assessment. Both dorsal horizon (skyline) views and ultrasonographic images were reviewed by the evaluators to determine whether any screws had breached the dorsal cortex and penetrated the extensor compartments. No significant difference was found between the methods in the second and third compartments. In the fourth compartment, no difference was observed for screw protrusions ranging from 0 to 2 mm. However, the accuracy for detecting 1 mm of screw protrusion was 87% with ultrasonography and 71% with radiography. The authors concluded that ultrasonography is a more reliable and effective method for detecting screw penetration into the dorsal extensor compartments (16).

Vernet et al. (16) compared the skyline fluoroscopic view with ultrasonography for detecting screw penetration into the extensor compartments. The detection rate was 43.33% with ultrasonography and 96.97% with the skyline view. The authors concluded that ultrasonography could not replace fluoroscopy. This finding contrasts with the results of our study, in which the detection rate of ultrasonography was nearly 85%.

In a clinical and cadaveric study, Balfour (19) reported that ultrasonography is useful for identifying excessively long screws, detecting intra-articular penetration, and preventing tendon irritation. De Maeseneer et al. (20) demonstrated that ultrasonography may also be used to diagnose injuries to the extensor pollicis longus tendon. Similar findings were reported by Santiago et al. (21).

Bianchi et al. (22) used ultrasonography to detect screw penetration into the dorsal compartments following volar plate fixation of distal radius fractures. The diagnosis was surgically confirmed in all nine patients who underwent reoperation. The authors correlated the in vitro ultrasonographic appearance with the in vivo appearance of a protruding screw tip, characterized by multiple hyperechoic lines, similar to the findings observed in our study. They concluded that, in addition to detecting screw penetration into the dorsal compartments, ultrasonography offers the added advantage of identifying extensor tendon injuries and tendon irritation before rupture occurs.

In our study, no statistically significant difference was found among the imaging methods; however, the small sample size may have limited our ability to detect such a difference. Nevertheless, ultrasonography provided better detection in three cases, reduced the time required to assess fracture reduction quality parameters, increased the surgical team's satisfaction regarding radiation exposure time, and helped resolve uncertainty concerning the adequacy of screw placement.

Intraoperative ultrasonography and fluoroscopy yielded similar results in assessing the adequacy of screws used for volar locking plate fixation of distal radius fractures. Although ultrasonography detected a greater absolute number of inadequately positioned screws, this difference was not statistically significant. Nevertheless, the findings demonstrated the feasibility of intraoperative ultrasonography. Further studies with more rigorous methodological designs and larger sample sizes are warranted.

## Conclusion

This study demonstrated that ultrasonography and fluoroscopy yielded similarly favorable results in identifying intra-articular screws and screws protruding beyond the dorsal cortex in a case series of distal radius fractures treated with volar plate fixation.

Further studies are needed to establish this method as a highly recommended approach, with the potential to substantially reduce ionizing radiation exposure for both the surgical team and patients, shorten operative time, decrease complication rates, and reduce the need for reoperation.

## References


1. Braga Júnior MB, Chagas Neto FA, Porto MA, Barroso TA, Lima ACM, Silva SM, et al. Epidemiologia e grau de satisfação do paciente vítima de trauma musculoesquelético atendido em hospital de emergência da rede pública brasileira. Acta Ortop Bras. 2005;13(3):137-40.
2. Chung KC, Shauver MJ, Yin H, Kim HM, Baser O, Birkmeyer JD. Variations in the use of internal fixation for distal radial fracture in the United States Medicare population. J Bone Joint Surg Am. 2011;93(23):2154-62.
3. Court-Brown CM, Caesar B. Epidemiology of adult fractures: a review. Injury. 2006;37(8):691-7.
4. Trease C, McIff T, Toby EB. Locking versus nonlocking T-plates for dorsally comminuted distal radius fractures: a biomechanical study. J Hand Surg Am. 2005;30(4):756-63.
5. Orbay JL, Touhami A. Current concepts in volar fixed-angle fixation of unstable distal radius fractures. Clin Orthop Relat Res. 2006;(445):58-67.
6. Thielke KH, Wagner T, Bartsch S, Echtermeyer V. Angularly stable radius plate: progress in treatment of problematic distal radius fracture? Chirurg. 2003;74(11):1057-63.
7. Jirangkul P, Jitprapaikulsarn S, Songpatanaslip T. Outcomes following temporary Kapandji pinning technique and distal radial LCP fixation for intra-articular fractures of the displaced distal radius. Tech Hand Up Extrem Surg. 2019;23(1):38-43.
8. Li J, Ma Z, Gao F, Ji Y. The measurement of dorsal radial tilt by X-ray and computed tomography. Rev Assoc Med Bras (1992). 2018;64(11):1007-11.
9. Kwon BC, Lee JK, Lee SY, Hwang JY, Seo JH. Morphometric variations in the volar aspect of the distal radius. Clin Orthop Surg. 2018;10(4):462-7.
10. Neuhaus V, Badri O, Ferree S, Bot AGJ, Ring DC, Mudgal CS. Radiographic alignment of unstable distal radius fractures fixed with 1 or 2 rows of screws in volar locking plates. J Hand Surg Am. 2013;38(2):297-301.
11. Brunner A, Siebert C, Stieger C, Kastius A, Link BC, Babst R. The dorsal tangential X-ray view to determine dorsal screw penetration during volar plating of distal radius fractures. J Hand Surg Am. 2015;40(1):27-33.
12. Pichler W, Windisch G, Schaffler G, Rienmüller R, Grechenig W. Computer tomography aided 3D analysis of the distal dorsal radius surface and the effects on volar plate osteosynthesis. J Hand Surg Eur Vol. 2009;34(5):598-602.
13. Sugun TS, Karabay N, Gurbuz Y, Ozaksar K, Toros T, Kayalar M. Screw prominences related to palmar locking plating of distal radius. J Hand Surg Eur Vol. 2011;36(4):320-4.
14. Riddick AP, Hickey B, White SP. Accuracy of the skyline view for detecting dorsal cortical penetration during volar distal radius fixation. J Hand Surg Eur Vol. 2012;37(5):407-11.
15. Gurbuz Y, Kucuk L, Gunay H, Ozaksar K, Sugun TS, Bilge O. Comparison of ultrasound and dorsal horizon radiographic view for the detection of dorsal screw penetration. Acta Orthop Traumatol Turc. 2017;51(6):448-50.
16. Vernet P, Durry A, Nicolau X, D'Ambrosio A, Collinet A, Botero Salazar S, et al. Detection of penetration of the dorsal cortex by epiphyseal screws of distal radius volar plates: anatomical study comparing ultrasound and fluoroscopy. Orthop Traumatol Surg Res. 2017;103(6):911-3.
17. Ozer K, Toker S. Dorsal tangential view of the wrist to detect screw penetration to the dorsal cortex of the distal radius after volar fixed-angle plating. Hand (N Y). 2011;6(2):190-3.
18. Ozer K, Wolf JM, Watkins B, Hak DJ. Comparison of 4 fluoroscopic views for dorsal cortex screw penetration after volar plating of the distal radius. J Hand Surg Am. 2012;37(5):963-7.
19. Balfour GW. Using ultrasound to prevent screw penetration. J Hand Surg Am. 2016;41(3):453-6.
20. De Maeseneer M, Marcelis S, Osteaux M, Jager T, Machiels F, Van Roy P. Sonography of a rupture of the tendon of the extensor pollicis longus muscle: initial clinical experience and correlation with findings at cadaveric dissection. AJR Am J Roentgenol. 2005;184(1):175-9.
21. Santiago FR, Plazas PG, Fernández JM. Sonography findings in tears of the extensor pollicis longus tendon and correlation with CT, MRI and surgical findings. Eur J Radiol. 2008;66(1):112-6.
22. Bianchi S, van Aaken J, Glauser T, Martinoli C, Beaulieu JY, Della Santa D. Screw impingement on the extensor tendons in distal radius fractures treated by volar plating: sonographic appearance. AJR Am J Roentgenol. 2008;191(5):W199-203.
23. Bergsma M, Brown K, Doornberg J, Sierevelt I, Jaarsma R, Jadav B. Distal radius volar plate design and volar prominence to the watershed line in clinical practice: comparison of Soong grading of 2 common plates in 400 patients. J Hand Surg Am. 2019;44(10):853-9.